

# An alternative subcoronary implantation technique decreases the risk of complete heart block after stentless aortic valve replacement

Zhigang Song, Eric J. Lehr<sup>1</sup>, Shaohua Wang<sup>2</sup>

Department of Cardiothoracic Surgery, Changhai Hospital, The Second Military Medical University, Shanghai, China, <sup>1</sup>Swedish Heart and Vascular Institute, Swedish Medical Center, Seattle, WA, USA,

<sup>2</sup>Division of Cardiac Surgery, The University of Alberta, Edmonton, Canada

**Address for correspondence:** Dr. Shaohua Wang, 2H2.34 Walter Mackenzie Centre, 8440 – 112<sup>th</sup> Street, Edmonton, AB - T6G 2B7, Canada. E-mail: shaohua.wang@albertahealthservices.ca

## ABSTRACT

**Context:** Stentless aortic valve prostheses have excellent hemodynamic profiles, but may be associated with an increased postoperative heart block when compared to conventional prostheses. **Aims:** To assess the effect of an alternative subcoronary implantation technique on postoperative complete heart block (CHB) and permanent pacemaker implantation (PPI) following aortic valve replacement (AVR) with stentless tissue valves. **Settings and Design:** A total of 130 consecutive patients undergoing AVR with stentless tissue valves by a single surgeon were studied retrospectively. **Materials and Methods:** A stentless tissue valve was implanted into 80 patients using the conventional modified subcoronary implantation technique, and 50 patients received a stentless tissue valve by an alternative subcoronary technique in which the inflow suture line is raised at the level of right-non coronary commissure. Data were collected at the time of hospital discharge and at 6–12 months postoperatively. **Statistical Analysis Used:** Independent samples *t*-test was used to compare continuous variables, and categorical variables were compared with the chi-square test. **Results:** Use of this new method reduced postoperative CHB (4.0% vs. 16.3%,  $P = 0.033$ ), with fewer patients requiring PPI in the early postoperative period (6.0% vs. 18.8%,  $P = 0.041$ ). Echocardiographic examination showed no differences in the effective orifice area, peak and mean aortic valve gradients, or left ventricular mass index between groups. Trivial or mild aortic regurgitation was found in 3.9% of patients with the conventional modified technique and 4.0% of patients undergoing the alternative technique, during follow-up ( $P > 0.05$ ). **Conclusions:** Compared to the conventional subcoronary implantation technique, the alternative subcoronary implantation technique reduces the incidence of new CHB and the requirement of PPI following AVR with stentless tissue valves while preserving mid-term hemodynamic function.

**Key words:** Aortic valve replacement, heart block, pacemaker, stentless aortic valve

## INTRODUCTION

Cardiac conduction defects are well-known complications of aortic valve surgery. Mechanical trauma to the

conduction system is the most common contributing factor. Higher degree atrioventricular block (AVB), although often reversible, may also necessitate permanent pacemaker implantation (PPI). It has been reported that the incidence of conduction defects requiring PPI in patients who underwent aortic valve replacement (AVR) with stented prosthetic valves ranges from 3 to 6%.<sup>[1-3]</sup> However, the need for PPI after AVR with stentless tissue valves is not well characterized.

Stentless tissue valve prostheses are most commonly implanted using the conventional modified subcoronary

Access this article online	
Quick Response Code:	Website: www.jcdronline.com
	DOI: 10.4103/0975-3583.91594

implantation technique. In this position, there is a risk of placing inflow sutures in the atrioventricular (AV) conduction system below the commissure between the right and non-coronary cusps [Figure 1a]. We previously reported that patients undergoing AVR with stentless tissue valves have increased need for PPI in the early postoperative period.<sup>[4]</sup> Therefore, we improved our technique for placing the inflow suture line when implanting the stentless tissue valve in the subcoronary position. We compared the incidence of new PPI insertion in patients receiving stentless tissue valves in the subcoronary position using two different implantation techniques. Additionally, the hemodynamic performance of the stentless tissue valve implanted using the new technique was assessed.

## MATERIALS AND METHODS

### Patients

All adult patients who underwent AVR with a stentless tissue valve (Freestyle® Heart Valve, Medtronic, Minneapolis, MN, USA) by a single surgeon between January 2001 and June 2009 were considered for inclusion in this retrospective study. Exclusion criteria were the presence of preoperative PPI or automated implantable cardioverter-defibrillator, concomitant other valve replacement, aortic root replacement, aortic root enlargement procedure or left ventricular aneurysmectomy, patients receiving allograft or autograft (Ross procedure) valves, previous or concurrent septal myectomy and concomitant maze procedure. Based on these criteria, we retrospectively reviewed the charts for all patients who received stentless tissue valves over the

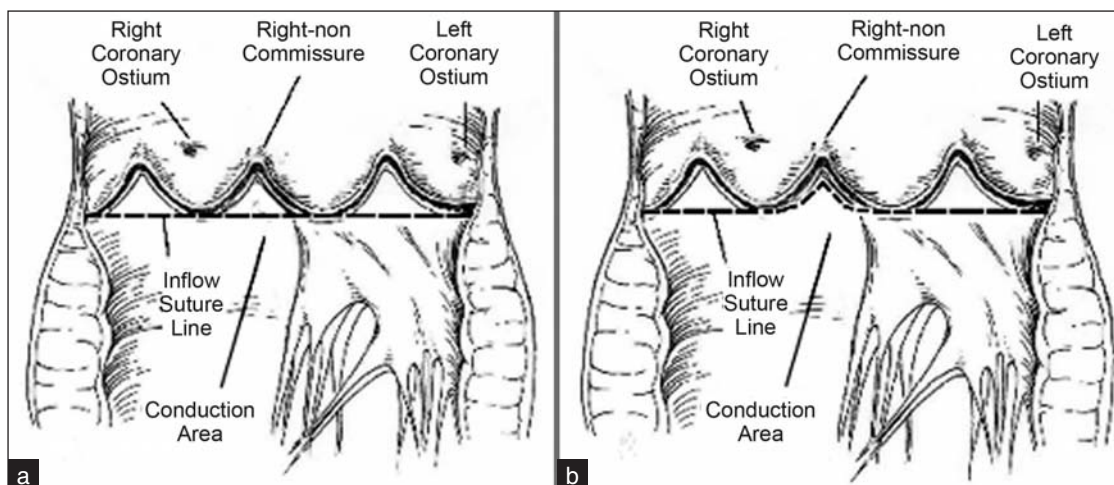
course of the study period. Patients were divided into two groups according to the implantation technique. The conventional modified subcoronary implantation technique was used in 80 patients and 50 patients underwent AVR using the alternative subcoronary implantation technique. Concomitant procedures included mitral valve repair and coronary arterial bypass grafting. Data collection was completed at the time of hospital discharge and at follow-up (97.7% complete at 6–12 months postoperatively). Patient records from each group were analyzed for clinical characteristics, electrocardiograms (ECGs), echocardiographic data, indication for surgery, postoperative complications, the development of new complete heart block (CHB) and the need for PPI in the early postoperative period.

### Electrocardiogram

Twelve-lead resting ECGs were recorded on a Hewlett-Packard electrocardiograph with a 0.05–100 Hz filter before and after operation. QRS duration, QT and QTc intervals were determined directly by the built-in-computer software. Experienced cardiologists performed analysis of the ECGs.

### Echocardiographic assessment

Echocardiographic assessment included M-mode and Doppler studies preoperatively and at 6–12 months postoperatively. Left ventricular ejection fraction (LVEF), left ventricular wall thickness, peak and mean aortic gradients, effective orifice area, and left ventricular mass were determined preoperatively and on follow-up examination. Prosthetic valve competence was assessed on the follow-up echocardiogram.



**Figure 1:** (a) The conventional modified subcoronary implantation technique. Inflow sutures are placed in a continuous fashion in a horizontal plane at the level of the nadir of the attachments of the native aortic valve leaflets to the aortic annulus. (b) The alternative subcoronary implantation technique. The inflow suture line is elevated at the right-non coronary commissure to minimize the risk of injuring the conduction system

## Surgical techniques

All operations were performed under standard cardiopulmonary bypass. Myocardial protection was achieved by direct infusion of cold hyperkalemic blood cardioplegia into the coronary ostium. A transverse aortotomy provided exposure of aortic valve. After excision of the aortic valve and annular debridement, the aortic annulus was sized. Stentless valves were inserted in the subcoronary position using the conventional modified subcoronary technique as previously described<sup>[5]</sup> ( $n = 80$ ) or using our alternative technique ( $n = 50$ ). In the conventional modified subcoronary technique, the inflow suture line was constructed using three continuous 4-0 polypropylene sutures placed below each commissure in a horizontal plane based on the level of the nadir of the attachments of the native valve leaflets to the aortic valve annulus [Figure 1a]. In the alternative technique, the inflow suture line was constructed in the same horizontal plane, but was raised at the level of right coronary commissure to avoid the conduction system [Figure 1b].

## Criteria for permanent pacemaker implantation

Patients with symptomatic second-degree AVB or third-degree AVB persisting more than 7 days postoperatively were considered for PPI according to the ACC/AHA/NASPE 2002 guidelines for the implantation of cardiac pacemakers and anti-arrhythmia devices.<sup>[6]</sup> An attending electrophysiologist determined the requirement for PPI.

## Statistical analysis

Statistical analysis was performed using SPSS 13 for windows (SPSS Inc., Chicago, IL, USA). Data were expressed as mean value  $\pm$  standard deviation and assumed a normal distribution for continuous variables and as numbers with percentage for categorical variables. Independent samples *t*-test was used to compare continuous variables, and the chi-square test was used to compare categorical variables. Results were assessed with a 95% confidential interval (CI) and *P* values  $<0.05$  were considered to be significant.

Our institutional Health Research Ethics Board approved the study protocol and waived the requirement for individual patient consent. The authors had full access to the data and took responsibility for their integrity. All authors have read and agreed to the manuscript as written.

## RESULTS

The clinical characteristics of the study patients are summarized in Table 1 which outlines the clinical

demographics of the two groups. Patients in both groups were homogenous with respect to age, gender, concomitant disease, preoperative diagnosis, left ventricular function, ECG and echocardiography characteristics.

Relevant operative and postoperative data are detailed in Table 2. There were three perioperative deaths, two patients (2.5%) in the conventional group and one patient (2.0%) in the alternative group ( $P > 0.05$ ). No differences in the incidence or type of concomitant operation and postoperative events were identified between groups. Aortic cross-clamp times were similar with both surgical techniques ( $P > 0.05$ ).

Use of the alternative subcoronary implantation technique dramatically reduced the development of CHB in the early postoperative period compared to patients who underwent conventional stentless aortic valve implantation (4.0% vs. 16.3%,  $P = 0.033$ ). This reduction in CHB translated into a reduced need for PPI in the alternative implantation technique group (6.0% vs. 18.8%,  $P = 0.041$ ).

Echocardiographic parameters were favorable in both stentless valve groups. Altering the subcoronary implantation technique had no impact on the effective orifice area, peak aortic gradient, mean aortic gradient, LVEF or left ventricular mass index. No patient in either group had clinically significant postoperative aortic regurgitation during follow-up. Trivial or mild aortic regurgitation occurred in 2 (4.0%) of patients who had stentless tissue valve replacement with the alternative subcoronary technique and in 3 (3.8%) patients who underwent the conventional technique. On follow-up echocardiography, there was no difference in the number of patients with aortic insufficiency or patient prosthesis mismatch between groups [Table 3].

## DISCUSSION

AVR is recommended for patients with symptomatic severe aortic valve disease. Debate exists regarding the selection of the best valve prosthesis to enhance surgical and long-term outcomes. As compared to traditional stented tissue valves, newer stentless tissue valves have been associated with early left ventricular remodeling and improvement in left ventricular function while providing superior hemodynamics.<sup>[7,8]</sup>

AV conduction disturbances requiring PPI have been a well-known complication of AVR since the introduction of the cardiac valve prosthesis in the early 1950s. Injury to the AV conduction pathways during AVR by annular decalcification,

**Table 1: Preoperative clinical and demographic characteristics for patients undergoing stentless aortic valve replacement**

Variables	Conventional technique (n = 80)	Alternative technique (n = 50)	P value
Age (years)	70.45 ± 9.28	72.98 ± 9.16	0.132
Male sex	51 (63.8)	37 (74.0)	0.224
Body mass index (kg/m <sup>2</sup> )	28.13 ± 5.54	28.72 ± 5.41	0.554
Hypertension	57 (71.3)	37 (74.0)	0.733
Diabetes	17 (21.3)	9 (18.0)	0.652
COPD	28 (35.4)	14 (28.0)	0.307
Congestive heart failure	15 (18.8)	10 (20.0)	0.860
Coronary artery disease	36 (45.0)	28 (56.0)	0.222
Previous MI	20 (25.0)	12 (24.0)	0.898
Previous cardiac surgery	2 (2.5)	3 (6.0)	0.313
Aortic stenosis	40 (50.0)	24 (48.0)	0.824
Aortic regurgitation	5 (6.3)	4 (8.0)	0.702
Aortic stenosis + regurgitation	35 (43.8)	22 (44.0)	0.978
Etiology of aortic valve			
Calcification	60 (75.0)	35 (70.0)	0.532
Endocarditis	3 (3.8)	1 (2.0)	0.578
Bicuspid	7 (8.8)	9 (18.0)	0.118
Other	10 (12.5)	5 (10.0)	0.664
Atrial fibrillation	5 (6.3)	4 (8.0)	0.702
Conduction disturbances			
First-degree AV block	10 (12.5)	8 (16.0)	0.574
LBBB	6 (7.5)	4 (8.0)	0.917
RBBB	7 (8.8)	5 (10.0)	0.811
Echocardiographic data			
LVEF (%)	54.31 ± 11.16	52.94 ± 10.19	0.482
LVEF <35%	7 (8.8)	5 (10.0%)	0.811
Effective orifice area (cm <sup>2</sup> )	0.88 ± 0.59	0.97 ± 0.69	0.456
Peak aortic gradient (mmHg)	68.31 ± 32.04	66.29 ± 25.73	0.708
Mean aortic gradient (mmHg)	39.89 ± 19.31	38.05 ± 15.24	0.566
LV mass index (g/m <sup>2</sup> )	127.77 ± 40.52	125.81 ± 33.29	0.775

AV: Atrioventricular; COPD: Chronic obstructive pulmonary disease; LBBB: Left bundle branch block; LVEF: Left ventricular ejection fraction; MI: Myocardial infarction; RBBB: Right bundle branch block. Figures in parentheses are in percentage.

**Table 2: Operative and postoperative data of patients undergoing stentless aortic valve replacement**

Variables	Conventional group (n = 80)	Alternative group (n = 50)	P value
Bypass time (min)	145.61 ± 47.93	147.51 ± 44.93	0.822
Cross-clamp time (min)	111.11 ± 26.36	111.62 ± 31.77	0.921
Prosthetic aortic valve diameter (mm)	23.65 ± 2.06	24.12 ± 2.11	0.211
Prosthetic aortic valve size ≤21 mm	16 (20.0)	9 (18.0)	0.778
Concomitant mitral valve plasty	2 (2.5)	3 (6.0)	0.313
Concomitant CABG	35 (43.8)	23 (46.0)	0.802
Hospital death	2 (2.5)	1 (2.0)	0.853
Postoperative complications			
LOCS	7 (8.8)	6 (12.0)	0.548
Pulmonary	14 (17.5)	9 (18.0)	0.942
Renal	7 (8.8)	5 (10.0)	0.811
Atrial fibrillation	29 (36.3)	16 (32.0)	0.620
First-degree AVB	1 (1.3)	1 (2.0)	0.735
LBBB	10 (12.5)	5 (10.0)	0.664
RBBB	4 (5.0)	1 (2.0)	0.387
CHB	13 (16.3)	2 (4.0)	0.033
PPI	15 (18.8)	3 (6.0)	0.041

AVB: Atrioventricular block; CABG: Coronary artery bypass grafting; CHB: Complete heart block; LBBB: Left bundle branch block; LOCS: Low cardiac output syndrome; PPI: Permanent pacemaker implantation; RBBB: Right bundle branch block. Figures in parentheses are in percentage.

suture placement and pressure on the conduction tissue can cause heart block requiring postoperative PPI.<sup>[9,10]</sup> AVB generally results from trauma to the AV node or His

bundle in the region of the membranous septum and right trigone beneath the non-coronary cusp–right coronary cusp commissure. PPI is required in approximately 6%



**Table 3: Postoperative echocardiographic data of patients during follow-up**

Variables	Conventional group (n = 78)	Alternative group (n = 49)	P value
Left ventricular ejection fraction (%)	54.67 ± 10.39	56.33 ± 10.29	0.381
Effective orifice area (cm <sup>2</sup> )	1.57 ± 0.42	1.68 ± 0.49	0.161
Peak aortic gradient (mmHg)	23.32 ± 10.86	20.97 ± 9.94	0.217
Mean aortic gradient (mmHg)	12.04 ± 5.94	10.64 ± 4.91	0.171
LV mass index (g/m <sup>2</sup> )	103.77 ± 40.46	99.61 ± 22.75	0.512
Prosthetic valve regurgitation			
1+	2 (2.6)	1 (2.0)	0.853
2+	1 (1.3)	1 (2.0)	0.735
3+	1 (1.3)	0 (0.0)	0.427
Prosthesis–patient mismatch	5 (6.4)	2 (4.1)	0.580

LV: Left ventricular; Figures in parentheses are in percentage.

of patients after isolated AVR and in up to 6.5% of patients after AVR with concomitant coronary artery bypass.<sup>[6-9]</sup> Patient-, surgeon- and valve-specific risk factors for AVB following AVR have been described. Bicuspid aortic valve, annular calcification, hypertension, preexisting conduction disturbances, previous myocardial infarction and total perfusion time are significant predictors of PPI postoperatively.<sup>[2,3,11,12]</sup> Totaro *et al.*<sup>[13]</sup> demonstrated that a continuous inflow suture line rather than interrupted sutures is associated with postoperative AV conduction defects and PPI.<sup>[13]</sup> Interestingly, it was recently reported that the incidence of heart block was strikingly higher in patients randomized to aortic root replacement with a Freestyle® valve compared to an allograft valve (9% vs. 0%,  $P < 0.01$ ). The authors did not suggest any reasons for this finding,<sup>[14]</sup> but it is possible that the more rigid sewing ring on the Freestyle® valve compared to a homograft valve exerts more pressure on the conduction tissue. Therefore, the Freestyle® valve may necessitate implantation further away from the conduction tissue, as we describe herein, than is necessary when implanting a homograft valve.

Limited data have been presented describing the development of irreversible AVB requiring PPI after AVR with stentless tissue valves. Recent studies reported the incidence of PPI following stentless tissue valve replacement to be as high as 8.3–19%.<sup>[15-17]</sup> We also previously reported that subcoronary stentless AVR is an independent predictor of postoperative heart block and the requirement for permanent cardiac pacing following AVR.<sup>[4]</sup>

During stentless valve implantation using the conventional modified subcoronary technique, the inflow sutures are placed below each commissure so that the suture line sits in a horizontal plane at the level of the nadir of the attachments of the native aortic valve leaflets to the aortic valve annulus. Consequently, the AV conduction system is liable to be injured when the inflow suture line is constructed beneath right-non commissure. In the current series, 16.3% of patients undergoing stentless tissue valve

implantation by the conventional modified subcoronary technique developed CHB in the early postoperative period.

To minimize the risk of trauma to the conduction system, we improved the conventional modified subcoronary technique by raising the inflow suture line at the level of the commissure of the right and non-coronary leaflets. Using this alternative subcoronary implantation technique reduced the incidence of postoperative CHB and PPI back to an incidence in keeping with AVR with conventional valves.<sup>[12]</sup>

When altering the position of the inflow suture line, care must be taken to avoid distortion of the prosthetic valve, which could adversely impact the hemodynamics and competency of the valve. In this series, peak and mean gradients were low in the alternative subcoronary technique group and were not different from stentless valves implanted with the conventional technique. Postoperative echocardiography in patients following stentless tissue valve replacement using alternative subcoronary technique identified 4.0% of patients with trace/mild aortic regurgitation; these outcomes are in accordance with previous reports<sup>[18]</sup> for stentless valve implantation. Our results suggest that the alternative subcoronary implantation technique does not adversely impact the hemodynamic performance of stentless tissue valves and can provide excellent short-term clinical results. With the inflow suture line moved closer to the coronary ostia, care must also be taken to avoid compromising coronary flow. In this study, no coronary occlusion or myocardial ischemia occurred in any patient (data not shown).

As with all retrospective studies, our analysis may be subject to inherent bias. To reduce selection bias, all patients undergoing AVR by a single surgeon during the study period were considered for inclusion in this study. Although patients were enrolled consecutively and were comparable, they were not randomized. It is also possible that learning curve issues or a bias from using historical

controls contributed to the differences in PPI between the two techniques. However, PPI was evenly distributed across patients in all time points throughout patients undergoing the conventional modified subcoronary technique and PPI rate fell immediately upon switching to the new technique. A much larger cohort investigation is required to confirm our findings regarding the alternative subcoronary implantation technique. Long-term studies are required to confirm excellent valve function at greater than 10 years.

Results from this study indicate significantly reduced requirement for PPI with the alternative method of subcoronary implantation of the stentless tissue valve. No adverse effect was determined by altering the position of the inflow suture line, and short to mid-term hemodynamic function of stentless tissue valves inserted using this technique remains excellent.

### ACKNOWLEDGMENT

We are indebted to Mary Ann James for her assistance in data collection and to Bin Liang for preparation of the graphics.

### REFERENCES

- Koplan BA, Stevenson WG, Epstein LM, Aranki SF, Maisel WH. Development and validation of a simple risk score to predict the need for permanent pacing after cardiac valve surgery. *J Am Coll Cardiol* 2003;41:795-801.
- Nardi P, Pellegrino A, Scafuri A, Bellos K, De Propriis S, Polisca P, *et al.* Permanent pacemaker implantation after isolated aortic valve replacement: Incidence, risk factors and surgical technical aspects. *J Cardiovasc Med* 2010;11:14-9.
- Limongelli G, Ducceschi V, D'Andrea A, Renzulli A, Sarubbi B, De Feo M, *et al.* Risk factors for pacemaker implantation following aortic valve replacement: A single centre experience. *Heart* 2003;89:901-4.
- Lehr EJ, Wang W, Mullen JC, MacArthur R, Ross D, Koshal A, *et al.* Abstract 2467: Stentless aortic valve replacement increases the requirement for permanent pacemaker. American Heart Association Scientific Sessions 2007. *Circulation* 2007;116:II\_543-a.
- Deeb DM. Aortic Valve Replacement with the medtronic freestyle xenograft using the subcoronary implantation technique. *Op Tech Thor Cardio Surg* 2006;11:173-84.
- Gregoratos G, Abrams J, Epstein AE, Freedman RA, Hayes DL, Hlatky MA, *et al.* ACC/AHA/NASPE 2002 Guideline Update for Implantation of Cardiac Pacemakers and Antiarrhythmia Devices—summary article: A report of the American College of Cardiology/American Heart Association Task Force on Practice Guidelines (ACC/AHA/NASPE Committee to Update the 1998 Pacemaker Guidelines). *J Am Coll Cardiol* 2002;40:1703-19.
- Kunadian B, Vijayalakshmi K, Thornley AR, de Belder MA, Hunter S, Kendall S, *et al.* Meta-analysis of valve hemodynamics and left ventricular mass regression for stentless versus stented aortic valves. *Ann Thorac Surg* 2007;84:73-8.
- Borger MA, Carson SM, Ivanov J, Rao V, Scully HE, Feindel CM, *et al.* Stentless aortic valves are hemodynamically superior to stented valves during mid-term follow-up: A large retrospective study. *Ann Thorac Surg* 2005;80:2180-5.
- ElKhally Z, Thibault B, Staniloae C, Theroux P, Dubuc M, Roy D, *et al.* Prognostic significance of newly acquired bundle branch block after aortic valve replacement. *Am J Cardiol* 2004;94:1008-11.
- Fukuda T, Hawley RL, Edwards JE. Lesions of conduction tissue complicating aortic valvular replacement. *Chest* 1976;69:605-14.
- Erdogan HB, Kayalar N, Ardal H, Omeroglu SN, Kirali K, Guler M, *et al.* Risk factors for requirement of permanent pacemaker implantation after aortic valve replacement. *J Card Surg* 2006;21:211-5.
- Dawkins S, Hobson AR, Kalra PR, Tang AT, Monro JL, Dawkins KD. Permanent pacemaker implantation after isolated aortic valve replacement: Incidence, indications, and predictors. *Ann Thorac Surg* 2008;85:108-12.
- Totaro P, Calamai G, Montesi G, Barzaghi C, Vaccari M. Continuous suture technique and impairment of the atrioventricular conduction after aortic valve replacement. *J Card Surg* 2000;15:418-22.
- El-Hamamsy I, Clark L, Stevens LM, Sarang Z, Melina G, Takkenberg JJ, *et al.* Late outcomes following freestyle versus homograft aortic root replacement – results from a randomized trial. *J Am Coll Cardiol* 2010;55:368-76.
- Elahi M, Usmaan K. The bioprosthesis type and size influence the postoperative incidence of permanent pacemaker implantation in patients undergoing aortic valve surgery. *J Interv Card Electrophysiol* 2006;15:113-8.
- Elahi MM, Osman KA, Bhandari M, Dhannapuneni RR. Does the type of prosthesis influence the incidence of permanent pacemaker implantation following isolated aortic valve replacement. *Heart Surg Forum* 2005;8:E396-400.
- Huynh H, Dalloul G, Ghanbari H, Burke P, David M, Daccarett M, *et al.* Permanent pacemaker implantation following aortic valve replacement: Current prevalence and clinical predictors. *Pacing Clin Electrophysiol* 2009;32:1520-5.
- Dagenais F, Cartier P, Dumesnil JG, Pibarot P, Lemieux M, Raymond G, *et al.* A single centre experience with the Freestyle bioprosthesis: Midterm results at the Quebec Heart Institute. *Semin Thorac Cardiovasc Surg* 2001;13:156-62.

**How to cite this article:** Song Z, Lehr EJ, Wang S. An alternative subcoronary implantation technique decreases the risk of complete heart block after stentless aortic valve replacement. *J Cardiovasc Dis Res* 2012;3:46-51.

**Source of Support:** Nil, **Conflict of Interest:** None declared.

### Announcement

#### Android App



Download  
**Android  
application**

FREE

A free application to browse and search the journal's content is now available for Android based mobiles and devices. The application provides "Table of Contents" of the latest issues, which are stored on the device for future offline browsing. Internet connection is required to access the back issues and search facility. The application is compatible with all the versions of Android. The application can be downloaded from <https://market.android.com/details?id=comm.app.medknow>. For suggestions and comments do write back to us.